72. Functional imaging of the lung parenchyma, tumours and circulation

374

Quantifying lung function in COPD with hyperpolarised ^{3}He MRI

Samuel Janoff[1], Helen Marshall[1], Martin Deppe[1], Cath Billings[2], Juan Parra-Robles[1], Sue Hillis[2], Sam Miller[3], David Lipson[4], Jim Wild[1], Rod Lawson[2]. [1]*Academic Radiology, University of Sheffield, United Kingdom;* [2]*Respiratory Medicine, Sheffield Teaching Hospitals NHS Trust, Sheffield, United Kingdom;* [3]*GlaxsoSmithKline, GlaxsoSmithKline, Stokley Park, United Kingdom;* [4]*GlaxsoSmithKline, GlaxsoSmithKline, King of Prussia, United States*

Introduction: Hyperpolarised ^{3}He MRI can identify regional lung defects and has been found more sensitive than spirometry to early changes in smokers lungs[1]. We aim to quantify change in lung function in response to bronchodilator in COPD using ^{3}He MRI.

Method: 10 patients with moderate to severe COPD (per NICE) were scanned pre and post bronchodilator at FRC+1L. Lung volume (LV) was defined by region growing algorithms (Slicer 3D, Harvard) on conventional ^{1}H MRI. Ventilated volume (VV) was defined by a threshold on ^{3}He MRI. Percentage ventilation (PV) was defined as VV/LV. Lungs were segmented into 4 regions on each slice with large airways removed.

Results: Change in ventilation, including recruitment of newly ventilated areas, was seen post treatment.

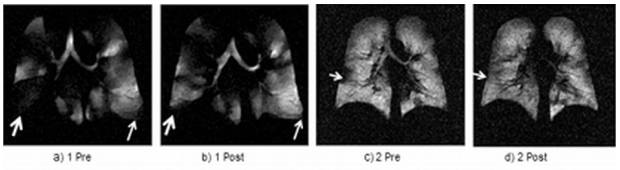

(Figure 1, Changes in ventilation: Patient 1 (a) pre bronchodilator (b) post and patient 2 (c) pre bronchodilator and (d) post. White arrows indicate region of change)

Regional analysis showed patterns of change in different lung areas which may be hidden in global measures.

FEV_1% significantly increased post treatment ($p<0.02$) suggesting geographical variation of lung recruitment significantly affects FEV_1, as opposed to global change in gas flow.

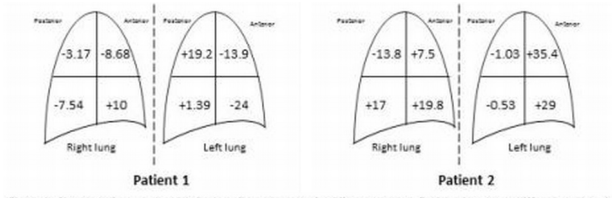

(Figure 2, Change in Percentage Ventilation after treatment in different regions. Each patient has a different pattern of change, illustrated here by the varied magnitude and direction of change in the same lung area of Patient 1 and 2.)

Conclusions: Global MRI measures and spirometry simplify lungs to one unit. Regional analysis explains better change in lung function.

Reference:

[1] JMR21:365-9(2005).

375

MRI of delayed-ventilation perfusion matching in COPD

Helen Marshall[1], Martin Deppe[1], Juan Parra-Robles[1], David Lipson[2], Rod Lawson[3], Jim Wild[1]. [1]*Academic Radiology, University of Sheffield, United Kingdom;* [2]*GlaxoSmithKline, GlaxoSmithKline, King of Prussia, United States;* [3]*Respiratory Medicine, Sheffield Teaching Hospitals NHS Trust, Sheffield, United Kingdom*

Introduction: Delayed ventilation in COPD may be caused by collateral ventilation, partial obstruction, lung hyperinflation or a mixture of such mechanisms, and allows initially-unventilated lung regions to become ventilated over time. Recently hyperpolarised gas MRI has been used to directly visualise delayed and collateral ventilation in COPD over the period of a single breath-hold. Delayed ventilation will only contribute to gas exchange if there is blood perfusion in these regions.

Objective: To image the perfusion matching of lung regions with delayed ventilation in COPD.

Methods: Ten patients with moderate to severe COPD as defined by NICE guidelines were scanned using ^{3}He and proton MRI. Delayed-ventilation images; hyperpolarised ^{3}He images with full lung coverage were acquired at six time-points during a single breath-hold. Contrast-enhanced perfusion images with full lung coverage were acquired at breath-hold.

Results: Regions of delayed-ventilation were perfused in some cases and were not perfused in others giving an indication of which areas remained active in gas exchange.

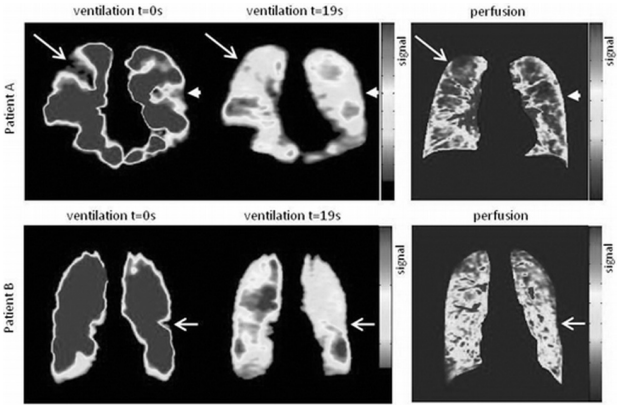

Example ventilation and perfusion images are shown in the figure. The defects with delayed-ventilation in patient A are not perfused, whereas the smaller defect in Patient B is perfused.

Conclusions: Hyperpolarised gas and proton MRI allow the visualisation of ventilation and perfusion matching, and may aid in the understanding of delayed-ventilation in COPD and its role in gas exchange.

376

MRI equilibrium signal mapping is a quantitative and reproducible alternative to CT for the estimation of lung density in COPD

Weijuan Zhang[1,2], Penny Hubbard[1,2], Eva Bondesson[3], Lars Wigström[4], Simon Young[5], David Singh[6], Josephine Naish[1,2], Geoffrey Parker[1,2,7]. [1]*Imaging Sciences, School of Cancer and Imaging Sciences, The University of Manchester, United Kingdom;* [2]*The Biomedical Imaging Institute, The University of Manchester, United Kingdom;* [3]*Semcon Drug Development Consulting, Semcon Caran AB, Lund, Sweden;* [4]*Respiratory & Inflammation Therapy Area, Clinical Development, AstraZeneca, Mölndal, Sweden;* [5]*Personalised Healthcare and Biomarkers, AstraZeneca, Alderley Park, United Kingdom;* [6]*Medicines Evaluation Unit, University Hospital of South Manchester Foundation Trust, Manchester, United Kingdom;* [7]*BiOxyDyn Limited, BiOxyDyn Limited, Manchester, United Kingdom*

In MRI, the equilibrium tissue magnetisation is proportional to tissue water density. This study aimed to explore the feasibility and reproducibility of mapping the signal (S_0) associated with the equilibrium magnetisation in the assessment of structural abnormalities in COPD.

MR images were acquired in 12 COPD subjects twice within 1 week for T_1 and S_0 mapping. Lung S_0 was normalized by dividing by muscle S_0 to obtain a quantitative S_0 (qS_0). Matched CT slices were selected to calculate PD_{15} and RA_{-950}.

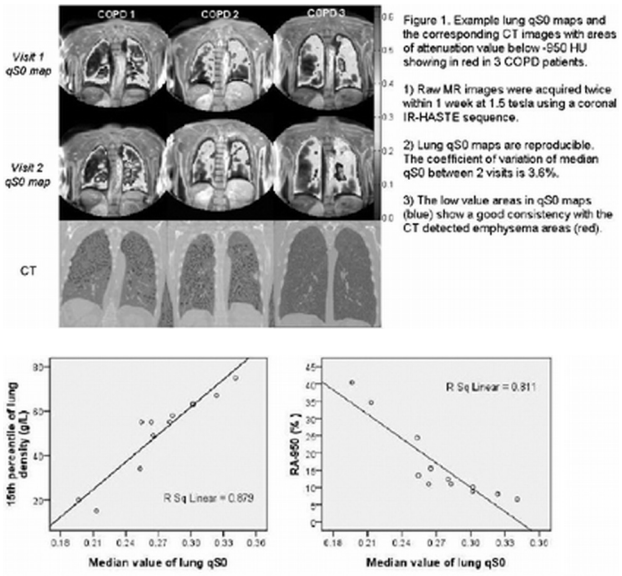

Figure 2. Scatter plots showing the correlation between median qS0 values and PD15 and RA-950 in COPD.
1) Left scatter plot shows a strong positive correlation between median value of lung qS0 and PD15.
2) Right scatter scatter plot shows a strong negative correlation between median value of lung qS0 and RA-950.

Table 1. Pearson correlation coefficient between lung qS_0 values and quantitative CT parameters

	Mean qS_0	15th centile qS_0	50th centile qS_0	75th centile qS_0
PD_{15}	0.930*	0.847*	0.938*	0.911*
RA_{-950}	–0.907*	–0.830*	–0.900*	–0.892*

*p value <0.01.

Lung qS_0 maps were reproducible with reduced values seen in regions comparable to CT detected emphysema regions. The mean and 15th, 50th, 75th percentile qS_0 showed strong correlations with PD_{15} and RA_{-950}.
Equilibrium signal maps of MRI correlate strongly with CT density estimates, indicating that qS_0 may be a reproducible, non-invasive/-ionising measure for quantifying lung density changes in COPD.

377

Measurement of airway inflammation in smokers by means of positron emission tomography

Sabine Garpered, Lars Edenbrandt, Sven Valind, Per Wollmer. *Dept. of Clinical Sciences, Lund University, Malmö, Sweden*

Smokers and subjects with chronic obstructive pulmonary disease (COPD) have neutrophilic inflammation in peripheral airways. Activated neutrophils are known accumulate ^{18}F-fluorodeoxyglucose (^{18}FDG). The aim of this study was to examine if inflammation in the lung in smokers can be detected with ^{18}FDG and combined positron emission tomography/computed tomography (PET/CT).
We recruited 22 current smokers and 23 never-smokers among subjects referred for diagnosis or staging of cancer with and ^{18}FDG and PET/CT. Subjects with focal abnormalities in ^{18}FDG lung uptake or CT were excluded. Other exclusion criteria were diabetes and suspicion of infection or interstitial lung disease. The right lung was segmented in the CT image and lung density measured. ^{18}FDG uptake was measured in standardised uptake values in the corresponding volume and corrected for lung density.
There were no significant differences in lung uptake of ^{18}FDG or lung density between smokers and never-smokers (0.49±0.11 vs. 0.49±0.10 and -772±56 HU vs. -750±50 HU, respectively). When corrected for lung density, lung uptake of ^{18}FDG was nine per cent higher in current smokers than in never-smokers (2.00±0.21 vs. 1.84±0.20, $p<0.05$).Increased uptake of ^{18}FDG in lung tissue in current smokers relative to never-smokers probably indicates inflammation in peripheral airways. Measurements of ^{18}FDG uptake in the lung may be useful for studies of the pathophysiology of airways disease in COPD and the relation between airway and systemic inflammation.

378

Within-breath specific gas volume variations (ΔSVg) assessed by four-dimensional computed tomography (4D-CT) in lung tumor patients

Francesca Pennati, Caterina Salito, Aurora Fassi, Guido Baroni, Andrea Aliverti. *Dipartimento di Bioingegneria, Politecnico di Milano, Milano, Italy*

ΔSVg between different lung volumes reliably estimate regional lung function (Salito et al, Radiology 2009). Here we assessed with voxel-resolution within-breath ΔSVg from 4D-CT images in 5 tumor patients. Each breathing phase (1 to 9) of the 4D-CT dataset was registered onto the reference (phase 0, i.e. end inspiration) using the Demons algorithm and subtracted from it in terms of SVg. Mean value of ΔSVg in lower (LL) and upper (UL) lobes were computed in both healthy (H) and tumor (T) lung. In H mean ΔSVg was significantly different between UL and LL ($p<0.001$) with higher values in UL. Mean ΔSVg increased by 0.8±0.3 ml/g in UL and 0.4±0.2 ml/g in LL. No significant inter-lobes differences were found in T ($p=0.8$): mean ΔSVg increased by 0.8±0.4 ml/g in UL and 0.6±0.3 ml/g in LL. Fig.1 shows within-breath ΔSVg maps of an exemplificative tumor lung and the mean ΔSVg is reported for each breathing phase separately for UL and LL.

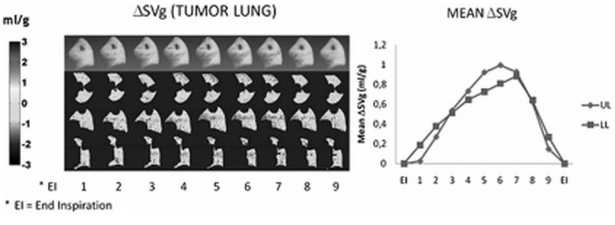

In conclusion: 1) ΔSVg maps applied to 4D-CT provide information about within-breath gas distribution in the lung; 2) in H there is higher ΔSVg in UL; 3) the presence of the tumor modifies ΔSVg distribution; 4) heterogeneous ΔSVg distribution suggests that areas with normal function could be identified as organs at risk during radiotherapy treatment planning.
Acknowledgments: Cancer Center Leon Berard, France
Funded by Fondazione U. Veronesi, Italy.

379

The role of dynamic magnetic resonance imaging in the evaluation of pulmonary nodules and masses

Fatih Alper[1], Adile Tuba Polat Kurt[1], Yener Aydin[2], Mesut Ozgokce[1], Metin Akgun[3]. [1]*Department of Radiology, Ataturk University, Erzurum, Turkey;* [2]*Department of Thoracic Surgery, Ataturk University, Erzurum, Turkey;* [3]*Department of Chest Diseases, Ataturk University, Erzurum, Turkey*

Objective: The aim of our study was to determine whether dynamic magnetic resonance imaging (MRI) with use of kinetic and morphological parameters reveals significant differences between malignant and benign pulmonary lesions, and thus to evaluate the utility of dynamic MRI in the management of pulmonary nodules.
Materials and methods: Thirty one patients (4 women and 27 men) underwent 1.5 T MRI, and 10 consecutive dynamic series were performed every 30 seconds by using 3D fast low-angle shot (FLASH) sequences. Percentage increase in signal intensity (%SI) of lesions was determined for each time point. Time-enhancement curves of the lesions were drawn and classified into four types (Type A, B, C, D). Early peak (EP) value and maximum peak (MP) value of the curves were calculated and compared with the patients' diagnosis. In addition of the comparison of the parameters between the groups, Receiver Operating Characteristics analysis was used to assess sensitivity, specificity, positive predictive value, negative predictive value of EP and MP parameters.
Results: Most of the malignant nodules showed stronger enhancement with higher EP and MP values. There were significant differences between benign and malignant lesions. Sensitivity, specificity, positive predictive value and negative predictive value were 75%, 93%, 92% and 78% for EP and 93%, 86%, 88% and 93% for MP, respectively.
Conclusion: A combination of kinetic and morphological evaluation in dynamic MRI provided accurate differentiation between benign and malign pulmonary lesions. It was a useful and noninvasive method of evaluating pulmonary nodules.
Key Words: Pulmonary nodules, dynamic MRI, kinetic parameters.

380

Non-invasive estimation of pulmonary artery pressure and resistance with CMR imaging: Derivation and prospective validation cohort study

Andrew Swift[1], Smitha Rajaram[1], Dave Capener[1], Tom Sproson[1], Allison Morton[2], Charlie Elliot[2], Robin Condliffe[2], Jim Wild[1]. [1]*Academic Unit of Radiology, University of Sheffield, United Kingdom;* [2]*Sheffield Pulmonary Vascular Disease Unit, Sheffield Teaching Hospitals NHS Trust, Sheffield, United Kingdom*

Background: The aim of this study was to develop a cardiac magnetic resonance (CMR) imaging model for non-invasive estimation of mean pulmonary arterial pressure (mPAP) and total pulmonary resistance (TPR).
Methods: A derivation cohort of 64 consecutive patients with known or suspected pulmonary hypertension underwent right heart catheterization (RHC) and CMR within 12hours. Cardiac volumes and function and pulmonary arterial (PA) flow were quantified. The strongest statistical model to predict mPAP from the derivation cohort was identified. Total pulmonary resistance (TPR) was estimated utilising the physiological model: TPR= pressure (CMR-derived mPAP) divided by blood flow (CMR-derived PA flow).
An independent prospective validation cohort of (n= 40) tested the accuracy of the model.
Results: The multivariate regression CMR model gave the following equation: mPAP = 33.4 + [right ventricular end-diastolic mass index (g/cm^2) x 1.21] – [PA average velocity (cm/s) x 0.99). In the prospective validation cohort, predicted and invasively measured mPAP were strongly correlated (R^2=0.74; $p<0.0001$). For detection of mPAP ≥ 25mmHg the area under the receiver operator curve (ROC) was 0.91 ($p<0.0001$). CMR-estimated TPR correlated strongly with RHC-derived TPR (R^2=0.75; $p<0.0001$) in the validation cohort. CMR estimated TPR reliably identified TPR > 5WU with a high degree of accuracy, the area under the receiver operator curve (ROC) was 0.96 ($p<0.0001$).
Conclusions: A CMR Imaging derived model can accurately estimate mPAP and vascular resistance in patients with PH.

381

MRI assessment of right atrial volume and function in pulmonary hypertension

Thomas Sproson, Andrew Swift, Smitha Rajaram, David Capener, David Kiely, Robin Condliffe, Charlie Elliot, Jim Wild. *Academic Unit of Radiology, University of Sheffield, South Yorkshire, United Kingdom*

Background: The role of the right atrium (RA) is under-researched within pulmonary vascular disease. The aim was to investigate the use of magnetic resonance imaging (MRI) derived RA volume and function in the diagnosis and management of pulmonary hypertension (PH).
Methods: Patients attending the pulmonary vascular clinic were retrospectively analysed. Inclusion criteria were cardiac MRI and right heart catheterisation within 48 hours.
Standard cardiac-gated balanced steady state free precession sequences were used. End-systolic volume (ESV) and diastolic volume (EDV) were calculated using Simpson's numeric integral applied to manual RA area tracings in the 4-chamber stack sequence.

Results: 71 PH patients were included, mean age was 65±15.5 years and 67.6% (48) were female.
RA function was shown to correlate with cardiac index (R=0.69) and mean RA pressure (R=-0.64), $P < 0.001$.
RA ejection fraction ≤ 28.3% was shown to have moderate sensitivity (80%) and specificity (71%) for identifying patients who met diagnostic criteria. RA ESV ≥48.0 ml was useful (sensitivity 96%, specificity 78%) for identifying patients with a high RA pressure, see figure 1.

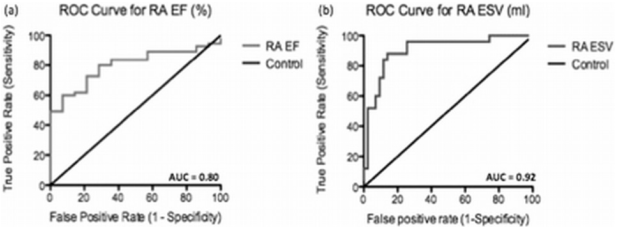

Figure 1. Receiver operator characteristic curves showing the diagnostic accuracy of (a) RA ejection fraction to detect a mean pulmonary artery pressure of ≥25 mmHg, (b) RA ESV to detect a mean RA pressure of >10 mmHg.

Conclusion: RA pressure is a known prognostic indicator; this study suggests high RA pressure can be detected using cardiac MRI. RA function has been shown to correlate well with haemodynamic measurements and clinical data. Further research into the natural history of RA volume change in PH is needed.