387. Diffuse parenchymal lung disease I

P3610

From basic lesions to a pathological staging of pulmonary fibrosis

Irina Stoia Djeska[1], Marius Raica[2], Alexandru Nicodin[3], Voicu Tudorache[1]. [1]*Pneumology, University of Medicine and Pharmacy, Timisoara, Timis, Romania;* [2]*Histopatology, University of Medicine and Pharmacy, Timisoara, Timis, Romania;* [3]*Thoracic Surgery, University of Medicine and Pharmacy, Timisoara, Timis, Romania*

Introduction: Pulmonary fibrosis is characterized by some morphological basic lesions which are associated to different degrees at the time of diagnosis. Based on this issue, a pathological staging of pulmonary fibrosis could be helpful to predict the evolution and the response to therapy.

Material and methods: We have quantified the severity of lesions on 20 patients with lung fibrosis namely: the aspect of the pulmonary parenchyma, the presence and density of the inflammatory infiltration, the density and distribution of the macrophages and the extension of fibrosis.

Specimens of lung parenchyma were obtained by video assisted thoracoscopy and slides were stained with routine haematoxylin-eosin, Masson's thricrome methods and Gordon Sweet silver stained. Each case was assigned a histological score on a scale of 0 – 12 and a degree of severity (I-IV).

Results: Four cases (20%) of degree IV (10-12) had a poor survival. There were found major changes of the parenchyma, extended nodular fibrosis and inflammatory infiltration as a marker for progressive evolution. Twelve cases (60%) of degree III (7-9) showed collagen fibres in homogenous fascicles and variable evolution and four cases (20%) of degree II (4-6) were more likely to remain stable. Collagen fibres were not organised in fascicles.

Conclusion: Histological score could represent a useful tool in the evaluation of pulmonary fibrosis and reflects its heterogeneity. Our results suggest that the actual scoring system of pulmonary fibrosis can be improved, to give more precise information about clinical outcome.

P3611

Th1/Th2/Th17-related cytokines in the bronchoalveolar lavage fluid of patients with sarcoidosis in relation to smoking

Tomasz Urbankowski[1], Grazyna Hoser[2], Rafal Krenke[1], Joanna Domagala-Kulawik[1]. [1]*Department of Internal Medicine, Pneumonology and Allergology, Medical University of Warsaw, Poland;* [2]*Laboratory of Flow Cytometry, Medical Center of Postgraduate Education, Warsaw, Poland*

Sarcoidosis (SA) a multiorgan granulomatous disease. The inflammatory process in involved organs is characterized by Th1/Th2 imbalance and participation of Th17 cells, what was recently documented. SA is more prevalent among non-smokers than in smokers, however the impact of cigarette smoking on inflammation in SA remains unclear.

The aim of the study was to evaluate the Th1/Th2/Th17-related cytokine concentrations in bronchoalveolar lavage fluid (BALf) of patients with pulmonary SA in relation to smoking status. 61 SA patients were investigated (26 ever (S) and 35 never smokers (NS)). The concentrations of IL-17A, INFγ, TNFα, IL-10, IL-6,IL-4 and IL-2 were measured by flow cytometry using Cytometric Bead Array method. The concentration of TNFα, IL-10, IL-4 and IL-2 was below minimum of detection in most cases. There was significant correlation of INFγ concentration with number of macrophages and between IL-6 concentration with number of neutrophils ($R=0.6$, $P<0.05$, $r=0.3$, $P<0.05$, respectively).

We found higher concentration of INFγ and lower of IL-6 in S than in NS (1.28 vs 1.23 and 1.66 vs 2.38, respectively, difference nonsignificant). The mean concentration of IL-17A was 6.1 pg/mL and did not differ between S and NS. There was significant correlation of IL-17A with IL-6 concentration ($R=0.9$, $p<0.05$) in the whole group and in S group. The concentration of IL-6 correlated negatively with the results of pulmonary function tests.

Our observation shows a slightly different profile of cytokine concentration in the BAL of smoking patients with SA. The lack of significance may be related to the short smoking history of patients.

P3612

Validation of a novel prognostic tool for idiopathic pulmonary fibrosis

Morven E.M. Wilkie, James D. Chalmers, Richard J. Stretton, Stuart Schembri, Robin P. Smith. *Respiratory Medicine, NHS Tayside, Dundee, United Kingdom*

Introduction: Idiopathic pulmonary fibrosis is a progressive disease with a median survival of 2-3 years. There is no universally accepted tool for identifying individuals with a poorer prognosis. du Bois et al [(1)] proposed a 4 point scoring system to predict 1 year mortality. This tool requires external validation.

Methods: Data was collected on 94 consecutive patients with IPF. The du Bois score was calculated based on age, respiratory hospitalisation, baseline forced vital capacity (FVC) and 6 month change in FVC. The predictive value of the score was assessed using the area under the receiver operator characteristic curve (AUC). Patients were followed up for at least 3 years or until death.

Results: Median age was 69 years (interquartile range 64-76). 57.4% were male. 1 year mortality was 10.6%. The 1 year mortality was 0% for those patients scoring 0-14 points, 11.5% for those with 16-21 points, 23% for those scoring 22-29 and 21% for those scoring>30 points.

For prediction of 1 year mortality, the AUC was 0.76 (95% CI 0.67-0.85,p=0.004) indicating moderate predictive value. For prediction of 3 year mortality, AUC was 0.72 (0.64-0.78,p=0.0005).

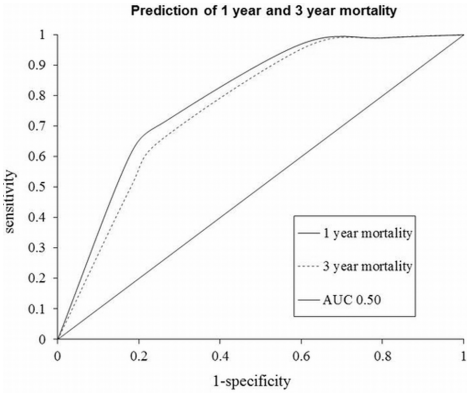

Conclusions: This study validates a novel risk score for prediction of outcome in patients with idiopathic pulmonary fibrosis.

References:

[1] du Bois, R.M. et al. Ascertainment of individual risk of mortality for patients with idiopathic pulmonary fibrosis. Am J Respir Crit Care Med 2011;184:459-466.

P3613

Expression of interleukin-27 (IL27) in human lower airways. Pathophysiological implications in pulmonary sarcoidosis (PS)

Piotr Kopinski[1], Tomasz Wandtke[1], Joanna Chorostowska-Wynimko[2], Grzegorz Przybylski[3], Ewelina Pólgesek[1], Andrzej Dyczek[2]. [1]*Dept. of Gene Therapy, Collegium Medicum, Nicolaus Copernicus University, Bydgoszcz;* [2]*Laboratory of Molecular Diagnostics and Immunology, Institute of Tuberculosis and Lung Diseases, Warszawa;* [3]*Dept. of Lung Diseases and Tuberculosis, Collegium Medicum, Nicolaus Copernicus University, Bydgoszcz, Poland*

Background: Interleukin-27 was recently discovered as a cytokine secreted by antigen presenting cells, participating in T cell priming and supporting Th1 type immune polarization. IL27 expression has not been examined yet in lower airways.

Aims: Identification of IL27 sources in human lower airways. Preliminary assessment of IL27 expression in bronchoalveolar lavage (BAL) in interstitial lung diseases (ILD) patients.

Methods: Intracellular IL27 expression cells was determined by indirect phenotyping and flow cytometry in BAL cells obtained from patients with PS (incl. steroid treated subjects), idiopathic pulmonary fibrosis (IPF) and controls, as well as in Human Lung Fibroblasts (HLF1) and pneumocyte type II (A549) cell lines. IL27 extracellular secretion was tested by ELISA (cat. no E90385Hu, Diaclone) in supernatants of BAL and cell cultures.

Results: BAL detectable IL27 levels were shown by ELISA in 6 (median 9ng/ml) of 13 PS untreated patients. IL27 was not found in BAL supernatants of steroid-treated PS, IPF and controls. HLF1, A549 and alveolar macrophages were positive for intracellular IL27. Surprisingly, IL27+ BAL lymphocytes were found in all tested groups (PS: 81±6.2%; IPF: 37±13.4%; controls: 46±15%, median±SEM, insignificant).

Conclusions: In physiological conditions, IL27 is produced in lower airways by lung fibroblasts, epithelial and BAL immune cells, including lymphocytes. Its increased expression in PS suggests IL27 to play a role in ILD pathophysiology, probably as Th1 activity marker.

P3614

Pulmonary graft-versus-host disease (GVHD) post- stem cell transplant (SCT) for haematological malignancies: Good response to treatment if diagnosed early

Bhagyashree Jayaraman[1], F. Begum[2], K. Raj[1], H. Milburn[1]. [1]*Department of Respiratory Medicine, Guys Hospital,Guys & St Thomas' NHS Trust, London, United Kingdom;* [2]*Medicine, Kings College, London, United Kingdom*

Introduction: Graft-Versus-Host Disease (GVHD) of the skin and gut are relatively common following allogeneic transplant for haematological malignancies but GVHD affecting the lung can be subtle.
In this study, we evaluated patients who developed lung GVHD post stem cell transplant (SCT) to determine early warning signs and response to treatment.
Method: Patients undergoing SCT for haematological malignancies were monitored with serial pulmonary function (PFT). Symptoms of increased breathlessness (SOB) or fall in PFT prompted investigation with high resolution CT scan(HRCT).
Results: 11 patients developed lung GVHD following allogeneic SCT for lymphoma (n=7) or leukaemia (n=4). 6 had adjuvant chemotherapy, and 7 total body irradiation. 10 had exertional SOB. 3 developed pulmonary GVHD within 1 year of SCT.
PFT changes are shown.

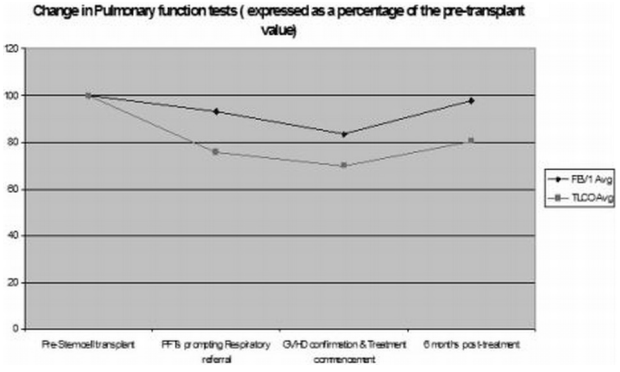

All patients had mosaicism with gas trapping on HRCT at diagnosis, and were commenced on steroids, with 6 having other immunosuppressants.
The post-treatment HRCT showed clearance in 10 patients (1 died due to relapse of malignancy).
Conclusion: Exertional SOB and changes in PFT are important early indicators of developing GVHD which can be confirmed on HRCT. Treatment with with immunosuppressants results in successful resolution in the majority, particularly in those who were diagnosed early in the course of this complication.

P3615

Response to physical exercise in sarcoidosis

Katarzyna Hildebrand, Tadeusz Przybylowski, Marta Maskey-Warzechowska, Joanna Wiwala, Ryszarda Chazan. *Department of Medicine, Pneumonology and Allergology, Warsaw Medical Univeristy, Warsaw, Poland*

The aim of this study was to analyze the response to exercise in untreated patients with pulmonary sarcoidosis. We recruited 39 patients (15 females) at mean age 39±9 years to undergo lung function testing (spirometry, bodyplethysmography, CO diffusing capacity) and symptom limited cardiopulmonary exercise test on a treadmill. Histological confirmation of sarcoidosis was obtained in 64% of patients; on the basis of radiologic findings 37% of patients were diagnosed with stage I, 51% with stage II and 11% with stages III and IV. Muscle fatigue was the main reason for exercise termination (82% of patients), followed by ECG abnormalities, blood pressure increase or vertigo and dyspnea reported by 10% and 5% of patients, respectively. Decreased exercise tolerance (defined as V'O2max < 82% of predicted) was diagnosed in 15 (38%). V'O2max in patients with decreased exercise tolerance was significantly lower than in patients with normal response to exercise (32.6±7.8 vs 27.6±6.6 ml O2/kg/min; $p<0.05$). Patients with impaired response also had a lower PaO2 at peak exercise (87.8±18.5 vs 100.1±7.6 mmHg; $p< 0.05$) and widened alveolar-capillary oxygen gradient (17.5±10.1 vs 7.9±8.1 mmHg; $p<0.05$). Some significant correlations between V'O2max and FEV1% pred. (r=0.40; $p<0.05$), FVC % pred. (r=0.43; p=0.008), RV/TLC (r=-0.41; $p<0.01$) were also noted.
Conclusions: Impaired exercise tolerance can affect up to 40% of patients with sarcoidosis. Lower PaO2 and widened alveolar-capillary oxygen gradient suggest an important role of gas exchange abnormalities in the pathogenesis of impaired response to exercise.

P3616

Isolated lymphocytic bronchiolitis with B cell clonality: Diagnosis in 3 cases using immunoglobulin gene rearrangement analysis

Irina Latu[1], Vincent Cottin[1], Françoise Thivolet-Bejui[4], Françoise Berger[3], Chahéra Khouatra[1], Baakar El Zoobi[1], Gilles Salles[2], Jean-François Cordier[1]. [1]*Respiratory Medicine - Reference Center for orphan Pulmonary Disease, Louis Pradel University Citty Hospital, Lyon, France;* [2]*Hematology, CH Lyon Sud, Lyon, France;* [3]*Pathology, CH Lyon Sud, Lyon, France;* [4]*Pathology, Louis Pradel University City Hospital, Lyon, France*

Background: Lymphocytic bronchiolitis is characterised by diffuse infiltration of the bronchiolar walls by lymphocytes, which may organise into germinal centres (follicular bronchiolitis). B cell clonality demonstration may result in a diagnosis of low- grade B-cell lymphoma
Patients and methods: Patient #1: 59-yr old female, non-smoker, presented with chronic cough, dyspnea, sicca syndrome, negative anti-SSA/SSB antibodies, severe airflow obstruction, ground glass opacities at HRCT, and 51% of lymphocytes at BAL. Patient #2: 54-yr old female, non-smoker, presented with chronic cough, restrictive lung disease, diffuse micronodules at HRCT, 90% lymphocytes at BAL, monoclonal IgG lambda of 4.2 g/l. Patient #3: 66-yr old female, non-smoker, with history of rheumatoid arthritis and Sjögren syndrome, anti-SSA and -SSB antibodies, presented with hemoptysis, Bence-Jones protein, airflow obstruction, 2 lung amyloid nodules and multiple cystic lung disease.
Results: Lung biopsy with immunohistochemistry demonstrated lymphocytic bronchiolitis in all three cases with a majority of CD 20 positive B –cell. PCR-based DNA testing for immunoglobulin gene rearrangement analysis of lung biopsy demonstrated B-cell clonality in all three cases (VK-JK, FR1-JH), and low-grade MALT lymphoma was eventually diagnosed.
Conclusions: Lymphocitis bronchiolitis may correspond to low-grade MALT lymphoma witch may be demonstrated by gene g rearrangements rearrangement analysis.

P3617

The relationship between leptin and proinflammatory cytokines with bone mineral density in patients with sarcoidosis (pts)

Elzbieta Puscinska[1], Michal Bednarek[1], Anna Goljan-Geremek[1], Anna Kowalczyk[1], Joanna Chorostowska-Wynimko[2], Paulina Jagus[2], Ada Rozy[2], Jacek Grudny[3], Dariusz Chmielewski[4], Dorota Gorecka[1]. [1]*2nd Department of Respiratory Medicine, National Institute of Tuberculosis and Lung Diseases, Warsaw, Poland;* [2]*Laboratory of Molecular Diagnostics and Immunology, National Institute of Tuberculosis and Lung Diseases, Warsaw, Poland;* [3]*3rd Department of Lung Diseases, National Institute of Tuberculosis and Lung Diseases, Warsaw, Poland;* [4]*Department of Orthopaedics and Traumatology of Locomotor System, Medical University of Warsaw, Poland*

Background: Sarcoidosis is a chronic inflammatory disease. Osteoporosis is a multifactor disorder of reduced bone mass. Body weight is commonly considered a significant predictor of bone mineral density (BMD) but obesity is also associated with chronic inflammation. Cytokines like TNF-α, IL-1 and IL-6 induce bone resorption and bone loss.
Aim: The aim of the study was to investigate whether there is a relationship between leptin or cytokines and BMD in pts.
Methods: 85 pts, none was treated with steroids, 46M and 39F, age 41±9y were enrolled. We evaluated BMI, serum leptin, TNF-α, IL-1 and IL-6, osteocalcin, alkaline phosphate and others. BMD was measured (DXA).
Results: Pts with low BMI had decreased lumbar spine BMD(Tscore<-1). The differences were statistically significant for group with normal BMI(18,5<BMI<25), compared to overweights (25<BMI<30), p=0,045 and to obese (BMI>30), p=0,00054. There were no such results for femoral neck BMD. The highest values of leptin were found in pts with obesity. The differences between pts with normal BMI compared to those with obesity was statistically significant (p=0,026). There was a weak correlation between leptin and BMI, R=0,25, leptin and IL-1,R=0,27, leptin and phosphate in urine, collected over 24h, R=0,31. No correlation was found between leptin and TNF-α or IL6.
Conclusions: In our group BMD was related to BMI but not to leptin levels nor other cytokines. Obesity, through its mechanical loading effect have a protective influence on bone tissue metabolism. Leptin, cytokines have a role in bone growth, development and loss. Further research is required to ascertain the importance of adipokines or cytokines for BMD.

P3618

Multi nodular parenchymal pulmonary amyloidosis in primary Sjogren's syndrome: A case report

Fatma Sema Oymak[1], Ozlem Canoz[2], Fatih Kurnaz[3], Mustafa Calis[4], Afra Yildirim[5], Nuri Tutar[1], Asiye Kanbay[1], Hakan Buyukoglan[1], Inci Gülmez[1], Ramazan Demir[1]. [1]*Department of Chest Diseases, Erciyes University Medical School, Kayseri, Turkey;* [2]*Department of Pathology, Erciyes University Medical School, Kayseri, Turkey;* [3]*Department of Internal Diseases, Hematology Unit, Erciyes University Medical School, Kayseri, Turkey;* [4]*Department of Physical Therapy and Rehabilitation, Erciyes University Medical School, Kayseri, Turkey;* [5]*Department of Radiology, Erciyes University Medical School, Kayseri, Turkey*

Amyloidosis is a rare cause of pulmonary infiltrates in primary Sjögren's syn-

drome(SS), affecting 0–2% of symptomatic patients. Diffuse multi nodular amyloidosis(DMNPA) is the most common radiological pattern, occurring alone or in association with cysts of varying size. Amyloid can be easily overlooked or mistaken for other entities with similar staining qualities. We describe the case of a 61-year-old woman with DMNPA (AL (λ)) related to SS, in the presence of primary systemic amyloidosis(PSA). She had suffering from cough, hemoptysis and dyspnoea of two -month duration. She had been diagnosed with SS 10 years previously. She had macroglossia and multiple skin nodules. Chest excursions were reduced with crackles in both lungs. Her chest radiograph and CT showed multiple nodules and cysts in both lung fields. Calcification in the nodules and lymphadenopathy were apparent in the mediastinal windows. Spirometry indicated moderate restriction, and BAL fluid was negative for acid-fast bacilli (AFB), fungi. Bronchoscopy with transbronchial lung biopsy revealed hyaline eosinophilic material associated with a giant cell granulomatous reaction, a patchy lymphocytic infiltrate. The congo red stain was positive in this hyaline material and showed apple green birefringence on polarising microscopy. Electrophoresis of serum proteins revealed hypergammaglobulinaemia. Serum immunofixation showed a monoclonal IgGλ. In the bone marrow (BM) plasma cells were increased to 10-15%. PSA (AL) associated with SS was diagnosed. Amyloid deposits were found not only in the lung but also in skin and BM biopsy specimens. Staining for amyloidosis should be performed in patient with SS and pulmonary infiltration.

P3619

Sarcoidosis is a frequent benign cause of lymphadenopathy in neoplastic patients

Claudia Ravaglia, Carlo Gurioli, GianLuca Casoni, Micaela Romagnoli, Sara Tomassetti, Christian Gurioli, Poletti Venerino. *Pulmonology Unit, Department of Thoracic Diseases, Pierantoni-Morgagni Hospital, Forlì, FC, Italy*

Background: Clinical and radiographic aspects of sarcoidosis and malignancy might mimic one another, making the distinction between the two difficult in some cases. Cancer and sarcoidosis have been associated in some case series from the literature but this association remains controversial. Objectives: a descriptive retrospective study to evaluate the incidence of sarcoidosis in patients followed-up for previous cancer and referred for hilar/mediastinal lymphadenopathies, with no pulmonary lesions.
Methods: We conducted a retrospective chart review of all patients who were referred to our pulmonology department in the period between January 2007 and Dicember 2011 with a new onset hilar/mediastinal lymphadenopathies during follow-up for previous neoplasms.
Results: Forty-eight patients (31 males, 17 females) of mean age 63 years (range 20-81) underwent EBUS/EUS trans-bronchial needle aspiration (TBNA). Patients had been followed-up for lung cancer (10 cases), lymphoma (9 cases), breast cancer (7 cases), urologic cancer (6 cases), gastro-intestinal tumors (6 cases), larynx/pharynx tumors (4 cases), gynecologic tumors (3 cases), other cancer (8 cases). Six patients had a history of two tumors or more in the past. Procedure was diagnostic in 45 patients (94%) and diagnosis was sarcoidosis in 12 patients (26,7%), metastasis from previous cancer in 13 patients (28,9%) and normal lymph node in 20 patients (44,4%).
Conclusions: Our study suggests that sarcoidosis should be considered in the differential diagnosis of patients with a history of malignancy who develop hilar/mediastinal lymphadenopathies; a tissue diagnosis should be obtained before instituting therapy for presumed cancer recurrence.

P3620

Clinical study of pulmonary hypertension complicating pulmonary Langerhans cell histiocytosis

Fei Li[1], Huaping Dai[1], Liying Peng[1], Mulan Jin[2], Chen Wang[3]. [1]*Department of Respiratory and Critical Medicine Care, Beijing Chao-Yang Hospital, Beijing, China;* [2]*Department of Pathology Medicine, Beijing Chao-Yang Hospital, Beijing, China;* [3]*Beijing Hospital, Health Ministry, Beijing, China*

Objective: To study the clinical features of pulmonary hypertension (PH) complicating pulmonary langerhans' cell histiocytosis (PLCH).
Methods: Medical records of 11 PLCH patients were reviewed from June 2006 to June 2011.
Results: 4 of the 11 PLCH patients presented PH with more severe clinical presentations. The major symptoms were laboring dyspnea and diminished exercise capacity (NYHA functional class IIIor IV), which were complicated with the sigh of right heart failure. The cystic change and pulmonary artery/main artery >1 were predominate on chest high-resolution computed tomography. Right heart enlargement was also found. As to pulmonary function presentation, the patients displayed severe carbon monoxide diffusing capacity impairment and significant hypoxemia. The pulmonary artery systolic pressure were highly increased. Besides the typical histopathological features presented, involvement of both arteries and veins was also observed. Oxygen and symptomatic therapy were essential in the part of clinical treatment. 3 of the 4 PLCH-PH received corticosteroids or chemotherapeutic agents, but the effect was not ideal. Only one case of PLCH-PH have a stable condition.
Conclusion: Pulmonary hypertension is a common complication of PLCH and seems to predict a poor prognosis. It is necessary to derive an early diagnosis and prevention.

P3621

BAL findings in idiopathic NSIP and IPF

Micaela Romagnoli, Claudia Ravaglia, Sara Tomassetti, Christian Gurioli, Carlo Gurioli, Gian Luca Casoni, Venerino Poletti. *Thoracic Diseases, Pulmonology Unit, Forlì, Italy*

The role of bronchoalveolar lavage (BAL) in differentiating idiopathic NSIP (iNSIP) and idiopathic pulmonary fibrosis (IPF) is still controversial. Some authors described that BAL lymphocytosis is more likely suggestive of NSIP rather than IPF, that BAL neutrophilia is more suggestive of IPF, whereas other authors reported that BAL findings are not discriminating between NSIP and IPF.
BAL findings were retrospectively assessed in 57 patients, 26 with a histologically proven diagnosis of iNSIP (surgical lung biopsy n=19, criobiopsies n=7), and 31 with a diagnosis of IPF. BAL was obtained before lung biopsy, or at the first patient evaluation for some of the IPF patients. All patients underwent bronchoscopy during stable clinical conditions, and BAL excluded malignancy and/or infections in all cases. All patients were discussed at a multidisciplinary approach.
BAL total and differential cell counts did not differ between iNSIP (20 fibrosing, and 6 cellular) and IPF. The median (range) lymphocytes% was 11.5 (2-75) in iNSIP, and 7 (1-48) in IPF; the median (range) neutrophils% was 10.5 (0-59) in iNSIP, and 20 (1-83) in IPF. In the iNSIP group (age 56±12 years) patients were significantly younger than in IPF (age 70±6.6; $p<0.0001$), with a predominance of females (iNSIP n=17; IPF=22). One patient in the iNSIP group (3.8%) and 15 patients in the IPF group (48%) died during follow up. BAL findings were not predictive of survival nor of changes in lung function.
In conclusion, BAL findings are not helpful to discriminate the diagnosis between iNSIP and IPF patients. However, these data suggest that there might be different clinical-biological phenotypes in both iNSIP and IPF patients.

P3622

BAL markers of alveolar/capillary abnormality in IPF

Ermanno Puxeddu, Alessia Comandini, Paola Rogliani, Assunta Porretta, Francesco Cavalli, Cesare Saltini. *Respiratory Medicine, University of "Tor Vergata", Rome, Italy*

Several lines of evidence suggest that alveolar-capillary abnormalities, including increased alveolar septal capillary density and pulmonary veno-occlusive disease,are characterizing feature of IPF and may play a role in its progression.This study assess altered capillary permeability,abnormal intra-alveolar coagulation and alveolar hemorrhage as markers of alveolar/capillary abnormality.
Methods: Bronchoalveolar lavage (BAL) samples from 62 subjects (53 IPF patients and 14 healthy volunteers) were evaluated for α2-macroglobulin (α2-M) and fibrinogen D-dimer (D-d) concentration by ELISA.D-d levels were comparatively assessed in blood as well.The numbers of haemosiderin laden macrophages were measured by Perls' stain and the intensity thereof assessed by the Golde score.
Results: IPF patients had markedly increased α2-M levels (mean 10000 vs 50 ng/ml, $p<0,0001$) and D-d were elevated with significantly higher frequency (39/62 vs 1/14, $p<0,05$) with no blood elevation.Golde scores were elevated (69 vs 19, $p<0,001$) compared to controls. α2-M concentration positively correlates with the Golde score ($p<0,05$) and D-d concentration ($p<0,05$).In patients with a high Golde score (Golde score>59) the D-d concentration (125 vs 17 $p<0,05$) was increased and both DLCO (43 vs 56%,$p<0,05$) and exercise capability (6MWTD 273 meters vs 415,$p<0,05$) were reduced vs patients with low score,while the FVC was not significantly different (82 vs 66%).Golde score and arterial pulmonary pressure showed significant correlation (R=0,39).
Conclusions: Leak of α2-M,intra-alveolar hemorrage and coagulation,indicate that alveolar-capillary abnormalities are important in the pathogenesis and progression of pulmonary fibrosis, and likely pulmonary hypertension in IPF.

P3623

Survival after surgical lung biopsy in patients with a histological pattern of non specific and usual interstitial pneumonias

B.J. Knipscheer[1], M.F.M. van Oosterhout[2], H.W. van Es[3], P. Zanen[4], C.H.M. van Moorsel[1], J.C. Grutters[1]. [1]*Department of Pulmonology, Center of Interstitial Lung Diseases, St. Antonius Hospital, Nieuwegein, Netherlands;* [2]*Department of Pathology, St. Antonius Hospital, Nieuwegein, Netherlands;* [3]*Department of Radiology, St. Antonius Hospital, Nieuwegein, Netherlands;* [4]*Division of Heart and Lungs, University Medical Center, Utrecht, Netherlands*

Background: Surgical lung biopsy involves a mortality risk, but is warranted to differentiate between fibrosing interstitial pneumonias with varying prognosis and response to therapy.
Objective: We evaluated 1 and 3- month mortality rate and post-operative course in patients with histopathological confirmed Usual Interstitial Pneumonia (UIP) and Non-Specific Interstitial Pneumonia (NSIP) after surgical biopsy.
Methods: Data and lung function were retrospectively collected from 1993 until 2008 from 57 patients that underwent surgical biopsy in our center that resulted in a histological pattern of UIP or NSIP. We analyzed 1 and 3- month mortality rate, post-operative hospital stay, drain removal, prolonged air leak and infectious complications.
Results: 1- month mortality rate was 5.1% (2/39) for UIP versus 0% (0/18) for NSIP. 3- month mortality rate was 10.2% (4/39) for UIP versus 0% for NSIP. No significant differences were observed in outcome measures. Notably, the NSIP

group had a worse pre-operative lung function than the UIP group. Mean forced expiratory volume in 1 second (FEV1) was 71% percent of predicted in NSIP versus 82% in UIP ($p< 0.05$) and NSIP had a lower mean diffusing capacity of the lung for carbon monoxide (DLCO) of 41% versus 51% in UIP patients ($p<0.023$).
Conclusion: After lung biopsy 3-month mortality in fibrosing interstitial pneumonias is relatively high (7%) and the majority (68%) of biopsies resulted in a UIP pattern. Four patients died within 3 months after biopsy all with a UIP pattern corresponding with a diagnosis of Idiopathic Pulmonary Fibrosis. This is remarkable because they had a significantly better pre-operative lung function.

P3624
A newly developed sling incorporating a shock absorber to minimize the motion effect on SpO_2 during the 6-minutes-walk test
Kenji Miyamoto, Yuya Tanaka, Toshiaki Kurimoto. *Department of Rehabilitation, Faculty of Health Sciences, Hokkaido University, Sapporo, Japan*

Recently, the degree of desaturation during 6-minute-walk test (6MWT) is considered to have prognostic value in patients with idiopathic pulmonary fibrosis. In this study, we demonstrate a negative effect of motion on SpO_2 during the walking, and present a newly developed device that minimizes the negative effect during the test.
Subjects and methods: Ten healthy volunteers (26±11yrs) performed 6MWT in 4 different manners: 1) usual walking, 2) usual walking while trying to minimize the effect of motion on the finger on which the oximeter-probe was placed, 3) usual walking using a newly developed sling with a shock absorber (75g) wrapped around the finger and the probe, and 4) walking on a treadmill at the same speed as the usual 6MWT while the finger and the probe were in a resting position without movement. SpO_2 was measured continuously using a Pulsox 300i (Konica-Minolta).
Results: During the usual walking with/without the finger moving, there was severe desaturation of more than 4% from the baseline. However, when walking with the new device or on the treadmill there was only a small change in the SpO_2, which was within the accuracy of the oximeter.

Motion effects on SpO2

Degree of desaturation	Usual walking	Walking while trying not to move the finger and the probe	Walking using the new device	Walking on the treadmill
2% > dSpO2 >4%	32.9±51.3	67.2±78.9	39.6±73.2	16.5±33.2
4% > dSpO2 >6%	13.2±39.6	14.5±38.0	0	0
6% > dSpO2	3.5±10.5	9.0±27.0	0	0

dSpO2= BaselineSpO2-desaturated SpO2, seconds.

Conclusions: SpO_2 monitoring during 6MWT does not provide reliable data on desaturation. However, using the new device, more reliable data on desaturation are available.

P3625
Effects of lymphadenopathy on pulmonary function tests in sarcoidosis
Omer Araz[1], Elif Yilmazel Ucar[1], Yener Aydin[2], Mehmet Meral[1], Yusuf Bilen[3], Fatih Alper[4], Ali Metin Görgüner[1], Metin Akgun[1]. [1]*Chest Department, Ataturk University, Erzurum, Turkey;* [2]*Thorasic Surgery, Ataturk University, Erzurum, Turkey;* [3]*Internal Medicine, Ataturk University, Erzurum, Turkey;* [4]*Radiology, Ataturk University, Erzurum, Turkey*

Background and objectives: The pulmonary function test (PFT) is an important quantification test in the follow-up of sarcoidosis. We aimed to investigate the effect of the presence of lymphadenopathy (LAP) alone or after controlling parenchymal involvement in PFT.
Materials and methods: A total of 63 sarcoidosis patients were enrolled retrospectively in the study. Respiratory functions were evaluated via PFT. Radiological evaluations of the patients were done with chest x-ray and high-resolution computerized tomography (HRCT). Bronchoscopic investigations were performed on all patients. Possible factors that affect PFT were evaluated.
Results: There is statistically significant correlation between the bronchoscopic findings and PFT parameters ($p<0.01$). Forced vital capacity (FVC) was affected more in the presence of LAP in bronchi neighbors, it was more or less the same for forced expiratory volume in the first second (FEV_1). Considering grade of HRCT findings, there is a statistically significant relation between FVC, FEV_1, and the presence of hilar LAP, intrahilar LAP and lober LAP ($p=0.001$). There is a statistically significant correlation with the presence of micronodules in HRCT and all parameters of PFT. These is a statistically significant negative correlation between the radiological stage of sarcoidosis and FVC, FEV_1.
Conclusion: We revealed that besides parenchymal involvement of the disease, special localization of lymph node involvement also has an important effect on the PFT parameters of sarcoidosis patients.

P3626
Airway-centered interstitial fibrosis – Two case reports
Vitor Melo, Marta Sousa, Jessica Jones, Ana Campos, Simões Torres. *Pneumology, Hospital São Teotonio, Viseu, Portugal*

Airway-centered interstitial fibrosis (ACIF) is a rare interstitial lung disease (ILD) of unknown cause characterized by chronic cough and progressive dyspnea and history of inhaled exposure. There is progressive peribronchiolar distribution of interstitial inflammation and fibrosis with bronchiolar metaplasia. The majority of patients are non-responsive to corticotherapy and prognosis is poor.
We describe two female patients, 65 and 66 years, presenting with chronic dry cough and progressive dyspnea. They were non-smokers, farmers and with a history of inhaled exposure to birds. Pulmonary function tests showed a moderate obstructive pattern in one case and moderately decreased CO diffusion in both patients. Chest radiographs revealed diffuse reticulonodular infiltrates. Chest computed tomography (CT) showed reticular fibrosis and disperse ground glass infiltrates in one case and sparing the upper lobes in the other. Bronchoalveolar lavage showed an increase in lymphocytes and neutrophils in one case. The diagnosis was made by surgical biopsy revealing pericentrilobular lesions and linfoplasmocitary infiltrate compatible with ACIF. Treatment with oral steroids for 12 months in both patients. In one case the disease progressed with worsening symptoms, pulmonary function tests and CT imaging even after combined immunosuppression with Azathioprine. In the other case the patient's symptoms and CT imaging improved.
These cases had similar clinical, radiological and pathological features as most of the few cases reported in literature. Both were non-smokers but had been exposed to birds. However, disease progression varied considerably as one patient improved but the other worsened even after combined immunosuppression.

P3627
Prevalence of beryllium sensitization in patients diagnosed with sarcoidosis
Romain Lazor[1], Vincent Aubert[2], Victor Dorribo[3], Peggy Chagnon Krief[3], Sandrine Ottesen Montangero[3], Pascal Wild[3], Gilles Bieler[3], Thomas Geiser[4], Dominique Valeyre[5], Michele Berode[3], Brigitta Danuser[3], the Swiss Group for Interstitial and Orphan Lung Diseases (SIOLD). [1]*Respiratory Medicine, Lausanne University Hospital, Lausanne, Switzerland;* [2]*Immunology and Allergy, Lausanne University Hospital, Lausanne, Switzerland;* [3]*Institute for Work and Health, University of Lausanne, Switzerland;* [4]*Respiratory Medicine, Bern University Hospital, Bern, Switzerland;* [5]*Respiratory Medicine, Hôpitaux Universitaires Paris-Seine-Saint-Denis (Avicenne), Paris, France*

Occupational exposure to beryllium (Be) may lead to development of Be-specific CD4+ T-cell immune response and occurrence of a granulomatous disorder called chronic beryllium disease (CBD). Due to similar clinical pictures, CBD may be misdiagnosed as sarcoidosis if Be exposure (BeE) and Be sensitization (BeS) are not looked for.
To determine whether some patients diagnosed as sarcoidosis may have undetected CBD, we screened a retrospective cohort of patients with sarcoidosis for BeE and BeS. BeE was assessed through a self-administered questionnaire and a standardized occupational health interview. BeS was assessed using CFSE flow cytometry developed as an alternative to the classical Be lymphocyte proliferation test (BeLPT). 159 patients recorded in a Swiss interstitial lung disease registry with a diagnosis of sarcoidosis were enrolled through their pulmonary physician and received a screening questionnaire. 68 filled questionnaires were returned. 28/68 patients had positive screening. 24/28 underwent an occupational health interview. BeE was considered probable in 6/24 and possible in 18/24. Using CFSE flow cytometry, BeS was detected in 7/24 of these patients (4/6 with probable BeE and 3/18 with possible BeE). BeS testing by CFSE flow cytometry was positive in 5/6 controls with proven CBD and positive BeLPT, and negative in 10 healthy subjects.
Conclusions: The minimal rate of BeE and BeS in an unselected population of patients with sarcoidosis was 7/159 (4.4%), suggesting misdiagnosed CBD. A screening questionnaire could help to detect BeE in patients diagnosed with sarcoidosis, and prompt investigations in search of CBD. CFSE flow cytometry may be an alternative to BeLPT to document BeS.

P3628
In vitro profibrotic effects of rapamycin on basal or TGF-β1 induced primary human lung fibroblast: ECM production and turnover, migration and differentiation
Xuefeng Xu[1,3], Xuan Wan[1,3], Jing Geng[1,3], Fi Li[1,3], Chen Wang[2,3], Huaping Dai[1,3]. [1]*Department of Respiratory and Critical Care Medicine, Beijing Chao-Yang Hospital, Capital Medical University, Beijing, China;* [2]*Beijing Hospital, Ministry of Health of China, Beijing, China;* [3]*Beijing Key Laboratory of Respiratory and Pulmonary Circulation Disorders, Beijing Institute of Respiratory Medicine, Beijing, China*

Introduction or background: Rapamycin (Rapa) is a multifunctional agent with unique properties such as anti-proliferation and fibrogenesis. However, the underlying mechanisms of Rapa's modulatory effects on fibrotic disorders still remain poorly understood. Recent remarks about the final and real modulatory effects of Rapa on fibrogenesis also seem rather controversial.
Aims and objectives: We addressed the question whether Rapa exerts its possible modulatory activity directly on extracellular matrix deposition and metabolism,

differentiation and migration of primary normal or fibrotic human lung fibroblast (HLFs) in vitro.
Methods: Fibroblasts were derived from lung tissue of idiopathic pulmonary fibrosis(IPF) patients and patients who suffered from primary spontaneous pneumothorax. Real time RT PCR was used for the assay of mRNA level of profibrotic cytokines in fibroblasts. Wound healing and migration assay was used for the mobility analysis of fibroblasts.
Results: We demonstrated that Rapa strongly amplifies the increase in basal or TGF-β1-induced fibronectin (FN), connective tissue growth factor (CTGF), TGF-β1, α-smooth muscle actin (SMA), tissue inhibitor of matrix metalloproteinase (TIMP)-1/plasminogen activator inhibitor (PAI-1) mRNA levels in normal or fibrotic HLFs. These positive functions of Rapa are in a Smad-independent way. Wound healing and migration assay showed that Rapa could not affect the mobility of HLFs.
Conclusions: These experiments demonstrate that Rapa positively regulates various gene expressions of HLFs. We suggest another evidence that Rapa may exert a profibrotic effects in vitro.

P3629

The markers of inflammatory process activity and fybrogenesis activity in patients with idiopathic pulmonary fibrosis

O.V. Karas'ova, E.S. Khmel, E.N. Kovalenko, V.V. Rodionova. *Hospital therapy and Profpathology, Dnepropetrovsk Medical Academy, Dnepropetrovsk, Ukraine*

Purpose: To define the inflammatory markers and severity of idiopathic pulmonary fibrosis (IPF).
Design: There were examined 29 patients with IPF (men - 21, women - 8) in the age of 35 - 57 years. Duration of disease was from 2-3 months till 2-3 years. Control group included 10 practically healthy persons (donors).
Methods: Common clinical methods, X-ray examination, definition of hemostasis parameters. The hardphase method of immune analysis was used for measuring level of plasma fibronectin (PFN) and lavage fibronectin (LFN). Patients had been examined during the period of disease aggravation.
Results: Patients with IPF had increased level of PFN and decreased activated blood recalcification time (ABRT) ($p<0,05$). The level of PFN was 319,211±14,769 mkg/ml, LFN - 0,055±0,011 mkg/ml and didn't depend on both sex and age. There existed straight connection between level of PFN and ABRT ($r = 0,4335$; $p<0,05$) and reverse connections between levels of PFN and LFN and level of plasma fibrin ($r =-0,5482$ and $r=-0,4969$; $p<0,05$). Severity of patients condition correlated with increased level of PFN.
Conclusions: Revealed inflammatory markers and changes in hemostasis system testify about activation of fybrogenesis and forming of chronic disseminated intravascular coagulation.